

Preventive Effect of 6-shogaol on D-galactosamine Induced Hepatotoxicity Through NF- κ B/MAPK Signaling Pathway in Rats

Xiufang ZONG^{1#}, Qian DING^{2#}, Xu LIU², Qianqian LIU², Shichao SONG², Xu YAN², Yan ZHANG²

[#]These authors contributed equally to this work

¹Department of Clinical Laboratory, Baoding First Central Hospital, Baoding, Hebei province, China, ²Department of Gastroenterology, Baoding First Central Hospital, Baoding, Hebei province, China

Received March 3, 2023

Accepted April 19, 2023

Summary

This analysis aims to see whether 6-shogaol could protect rats against D-galactosamine (D-GalN)-induced Hepatotoxicity. The Wistar rats were divided into four groups (n=6). Group 1 received a standard diet, Group 2 received an oral administration of 6-shogaol (20 mg/kg b.wt), Group 3 received an intraperitoneal injection of D-GalN (400 mg/kg b.wt) on 21st day, and Group 4 received an oral administration of 6-shogaol (20mg/kg b.wt) for 21 days and D-GalN (400 mg/kg b.wt) injection only on 21st day. The hepatic marker enzymes activity, lipid peroxidative markers level increased significantly and antioxidant activity/level significantly reduced in D-GalN-induced rats. 6-shogaol Pretreatment effectively improves the above changes in D-GalN-induced rats. Further, inflammatory marker expression and MAPK signaling molecules were downregulated by 6-shogaol. These findings showed that 6-shogaol exerts hepatoprotective effects via the enhanced antioxidant system and attenuated the inflammation and MAPK signaling pathway in D-GalN-induced rats.

Key words

6-shogaol • D-galactosamine • Antioxidant • Inflammation • MAPK

Corresponding author

Yan Zhang, Department of Gastroenterology, Baoding First Central Hospital, Baoding, 071000, Hebei province, China. Email: zhangyan127195@sina.com

Introduction

The liver is a crucial organ vulnerable to various causes, such as alcohol, chemical compounds, oxidative

products, and hepatitis viruses. This all-cause liver injury and even more severe hepatic cell destruction. Liver-related disorders have been viewed as a grave menace to individuals worldwide due to their high morbidity and mortality rates [1]. D-Galactosamine (D-GalN) is a known hepatotoxic drug that causes liver injury similar to the necrosis, inflammation, and regeneration seen in human viral hepatitis [2]. D-galactosamine alters uridine diphosphate (UDP)-glucose and UDP-galactose, causing intracellular calcium homeostasis to be disrupted and hepatocyte energy consumption to be inhibited. These alterations impact cell membranes and organelles and protein and nucleic acid synthesis, all of which contribute to the reported liver damage [3]. Subsequently, damage to organelles and hepatocyte necrosis takes place. D-GalN directly promotes mast cells to release histamine and Kupffer cells to release tumor necrosis factor-alpha, both of which promote cell death in various methods, including oxidative stress raising and inflammatory process [4].

Nuclear factor kappa B (NF- κ B) is a protein transcription factor with a long history. In acute liver injury, the activation of the NF- κ B signaling pathway plays a vital role. NF- κ B coordinates several signals that drive cell activation and proliferation during immunology, inflammation, and oncogenesis [5]. Numerous studies have demonstrated that decreasing NF- κ B activity effectively increases liver damage or fibrosis regression. Moreover, mitogen-activated protein kinases (MAPKs) are a family of serine-threonine protein kinases. MAPKs control cell growth, proliferation,

differentiation, and particular metabolic pathways [6]. An extracellular signal-regulated kinase (ERK), p38 kinase, and the primary inflammatory kinase c-Jun N-terminal kinase are MAPK family members (JNK). Activation of MAPKs in the liver of rats is associated with cell death through oxidative stress [7]. Consequently, addressing the NF- κ B and MAPK signaling pathways is likely a helpful therapy method for preventing liver injury from worsening.

Natural products are essential for developing novel anti-hepatitis medications to treat inflammatory liver problems [8]. Ginger (*Zingiber officinale*) is a food spice used in traditional medicine for cooking and disease swarm therapy [9]. 6-shogaol, a dietary agent, is a crucial bioactive element in ginger; it has medical benefits, antioxidant [10], anti-inflammatory [11] and anticancer [12]. Sapkota et al. discovered that 6-shogaol and its metabolite, 6-paradol, have neuroprotective properties in a mouse model of multiple sclerosis [13]. Bischoff-Kont et al. reported that the 6-shogaol inhibits inflammation- and angiogenesis-related cell functions in primary human endothelial cells [14]. 6-shogaol is a potential treatment for head and neck squamous cell carcinoma in SCC4 and SCC25 cells [15]. Furthermore, 6-shogaol treatment prevented articular cartilage lesions, synovitis and the presence of pro-inflammatory mediators, and disease markers in osteoarthritis animals [16]. This study aimed to evaluate the antioxidant and anti-inflammatory effects of 6-shogaol on rats with D-GalN-induced Hepatotoxicity. This study aims to examine the impact of 6-shogaol on NF- κ B and MAPK signaling pathways in lowering the inflammatory response and cell death.

Materials and Methods

Chemicals

D-Galactosamine and 6-shogaol were obtained from Sigma-Aldrich. Rabbit phosphorylated p38, JNK, ERK and β -actin primary antibodies and goat anti-rabbit IgG HRP-conjugated secondary antibodies were obtained from Santa Cruz Biotechnology, USA.

Animals and ethical statement

This study used 24 male Wistar rats weighing approximately 180-200 g each. Rats were confined to a chamber with regulated air conditions (temperature $24 \pm 1^\circ\text{C}$, humidity 50-65 %), a 12-hour light-dark cycle, and free access to sterilized food and water. The Animal Welfare and Research Ethics Committee of Baoding First Central Hospital, Hebei, China, examined and authorized all animal research.

Experimental procedure for induction of hepatotoxicity

According to Najmi et al. [17] and Radhiga et al. [18] reported that the hepatotoxicity produced by D-GalN induction by intraperitoneal injection (400 mg/kg BW) in freshly generated physiological saline.

Experimental design

The animals were assigned into four groups of six rats, each at random. Control animals were given a vehicle solution of 6-shogaol 20 mg/kg dissolved in 0.05 % dimethyl sulfoxide (DMSO). Annamalai and Suresh [12] reported that the 6-shogaol 20 mg/kg bt. had an effective dose compare to other doses. According to the reference we selected for this dose in this study (Table 1).

The entire experimentation duration was 21 days. At the end of the experiment (i.e. the 22nd day), the rats were anaesthetized, then sacrificed and their blood was collected for serum and plasma separation. The liver tissue was promptly extracted, washed with cold isotonic saline, and stored at -80°C for further analysis.

Activities of liver marker enzymes

Assessing hepatocyte injury by measuring aspartate aminotransferase (AST) and alanine aminotransferase (ALT) enzyme activity (ALT). ALT and AST serum levels were determined using test kits from the Jiancheng Bioengineering Institute of Nanjing. 5 μl of buffer solution, 20 μl of substrate solution and 2 μl of 2 mmol/L sodium pyruvate solution were added and mixed well to were added to 5 μl of serum and then incubated at 37°C for 30 mins. After incubation, 20 μl of

Table 1. Experimental study plan

Group I	Rat received a standard pellet diet for 21 days
Group II	Rat received 6-shogaol (20mg/kg b.wt, oral administration) for 21 days
Group III	Rat received an intraperitoneal injection of D-GalN (400 mg/kg b.wt) on the 21st day only
Group IV	Rat received 6-shogaol (20mg/kg b.wt, oral administration) for 21 days and D-GalN (400 mg/kg b.wt) injection only on the 21st day.

chromogenic agent was added, mixed with 10s and incubated at 37 °C for 20 mins. 200 µl of alkali reagent was added and mixed well; then stand for 15 mins at RT and measure the OD value of each well with microplate reader at 510 nm.

Histopathology

The liver of the rat was excised and quickly fixed in a 10 % formalin buffer solution for pathological examination. Fixed tissues were usually paraffin-embedded, and 5-µm slices were produced and stained with Haematoxylin and Eosin (H&E) stain before being mounted in a neutral deparafinated xylene solution according to standard techniques. An optical microscope was used to examine stained areas.

Analysis of the MDA and antioxidant status

The livers were homogenized (10 %) in the appropriate buffer at 4 °C and centrifuged for 20 minutes at a speed of 3000g. To level of Malondialdehyde (MDA) content was estimated by the commercial kit (Nanjing Jiancheng Bioengineering Institute, China). The following protocol estimated MDA. 200 µl of sample and added 600 µl of TBA solution to generate 800 µl of MDA-TBA adduct then incubated at 95 °C for 1 h; placed with on ice bath for 15 min. After incubation, the reaction mixture was measured at 532 nm on the microplate reader.

GSH was estimated by a commercial kit (Nanjing Jiancheng Bioengineering Institute, China). 5 µl of homogenate was pipetted out and precipitated with 2.0 ml of 5 % TCA. 2.0 ml of supernatant was taken after centrifugation and added 1.0 ml of Ellman's reagent and 4.0 ml of 0.3M disodium hydrogen phosphate. The yellow color developed was read in a Spectronic 20 at 412 nm. SOD is based on inhibition of the formation of NADH-phenazinemethosulphate, nitrobluetetrazolium formazon. The reaction is initiated by the addition of NADH to assay mixture. After incubation for 90 s, glacial acetic acid was added to stop the reaction. The color developed at the end of the reaction was extracted into n-butanol layer and measured at 520 nm. The following procedure assayed Catalase (CAT) activity. Dichromate in acetic acid was converted to perchromic acid and then to chromic acetate when heated in hydrogen peroxides (H₂O₂). The chromic acetate formed was measured at 620 nm. The catalase preparation was allowed to split H₂O₂ for various periods. The reaction was stopped at different time intervals by adding a dichromate-acetic

acid mixture and the remaining H₂O₂ as chromic acetate was determined microplate reader. The known amount of enzyme preparation assayed that the glutathione peroxidase activity (GPX) was allowed to react with H₂O₂ and glutathione (GSH) for a specified time. Then, the GSH content remaining after measured the reaction.

Measurement of inflammatory cytokines

Using an ELISA kit and the instructions from the manufacturer (BioLegend, Inc., CA, USA), TNF-α, IL-6, and IL-1β were measured by the following protocol. 50 µl of the sample and 50 µl of an antibody cocktail were added to the experimental wells. The reaction mixture was incubated at 37 °C for one hour. 3,3',5,5'-Tetramethyl-benzidine substrates (100 µl) were used to wash the experimental wells before they underwent a 10-minute incubation period. At the end of the reaction, 100 L of stop solution was added to the chosen wells, and the color developed was then read using an ELISA reader at OD 450 nm.

Inflammatory gene expression determination by real time-PCR

According to the manufacturer's protocol, the RNeasy Mini kit extracted total RNA from liver tissue. (Qiagen, USA). Real-time PCR was used to assess the mRNA expression of TNF-α, IL-6, NF-κB, and COX-2 in liver tissue (Eppendorf, Thermocycler, USA). The primer sequence was

	was	TNF-α
F:	GTACTAACTCCCAGAAAAGCAAGC	and
R:	CAGTAGACAGAAGAGCGTGGTG,	IL-6
F:	CAATGCTCTCCTAATGGAGAAGTTA	and
R:	ATGTCCACAACTGATATGCTTAGG,	NF-κB
F:	ATTCACATAGCTGTGATGAGCAAC	and
R:	AACGAGATGTTGTCGTACTIONCAC,	COX-2
F:	ATCCCGCCCTGCTGGTGGAA	and
R:	TGGTAGGCTGCGGGTCTTGC.	

Gene expression levels in each sample were standardized to GAPDH mRNA. Using the $2^{-\Delta\Delta Ct}$ formula, the relative gene expression was calculated using the mean Ct values from triplicate experiments.

Determination of MAPK signaling by western blot analysis

According to a previous study, liver tissue was homogenized with RIPA buffer [19]. The protein samples were equally distributed over the 10 % SDS-PAGE gel before being transferred to the PVDF membrane. The nonspecific binding proteins were inhibited with 5 %

BSA for one hour. The membrane was subsequently incubated with primary antibodies against phosphorylated p38, JNK, and ERK at 4 °C overnight. After this reaction, the membranes were incubated at room temperature for 2 hours with HRP-linked secondary antibodies. The membranes were washed three times at 10-minute intervals, and ECL western blotting substrate reagent was used to detect the bands.

Statistical analysis

The groups were compared using Duncan's Multiple Range Test (DMRT) and one-way analysis of variance (ANOVA) using SPSS Software Package, version 25. The results were expressed as means standard deviation for each set of six rats. A value of $P \leq 0.05$ was

considered statistically significant.

Results

Activities of serum liver marker enzyme

Fig. 1. shows the influence of 6-shogaol on D-GalN-induced liver enzyme activities in rats is examined using serum measurements of AST and ALT. The results show that the activities of AST, and ALT were increased significantly in D-GalN-induced rats ($P \leq 0.05$), compared to control rats. However, the 6-shogaol pretreatment significantly reduced the activities of AST and ALT ($P \leq 0.05$) compared to D-GalN-induced rats.

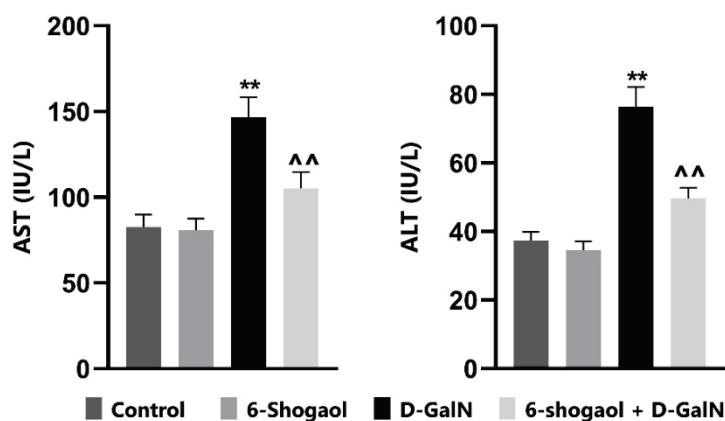


Fig. 1. Effect of 6-shogaol on hepatic marker enzymes in the serum of D-GalN induced hepatotoxic and control rats. All data are presented as means \pm SEM ($n = 6$ in each group). ** $p < 0.05$ vs. control group; ^^ $p < 0.05$ vs. D-GalN group.

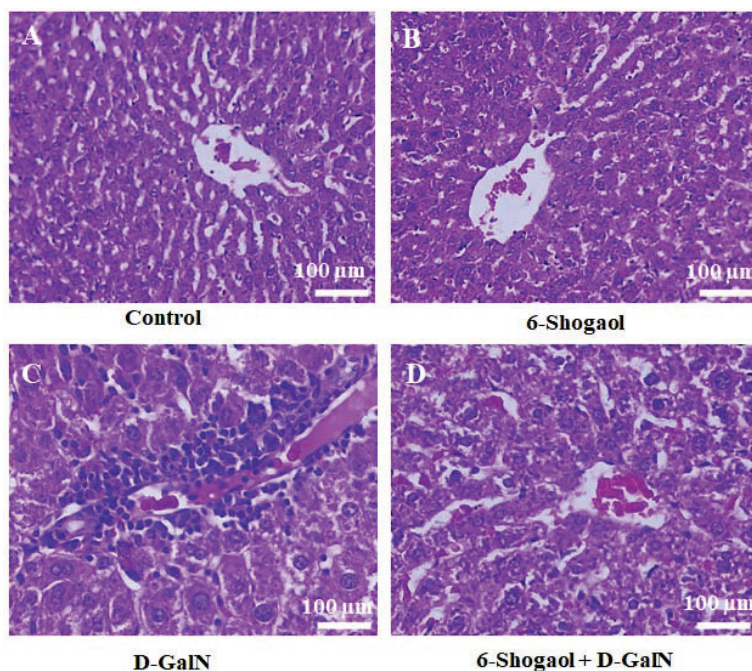


Fig. 2. Effects of 6-shogaol on histopathology of liver of D-GalN induced hepatotoxic and control rats. Control (A) and 6-shogaol control (B) groups had normal cellular and lobular architecture. D-GalN group displayed severe inflammatory cell infiltration, widespread portal vein inflammation, and cell necrosis (C). 6-shogaol pretreatment group, the severity of the histological damage brought on by D-GalN was only slight (D)

Histopathological observations

Fig. 2. depicts histopathological research on the impact of 6-shogaol in the liver of D-GalN-induced rats. The liver tissues in the control group had typical cellular and lobular architecture (Fig. 2 A&B). In contrast, the D-GalN group displayed severe inflammatory cell infiltration, widespread portal vein inflammation, and cell necrosis (Fig. 2C). In the 6-shogaol pretreatment group, the severity of the histological damage brought on by D-GalN was only slightly reduced (Fig. 2D).

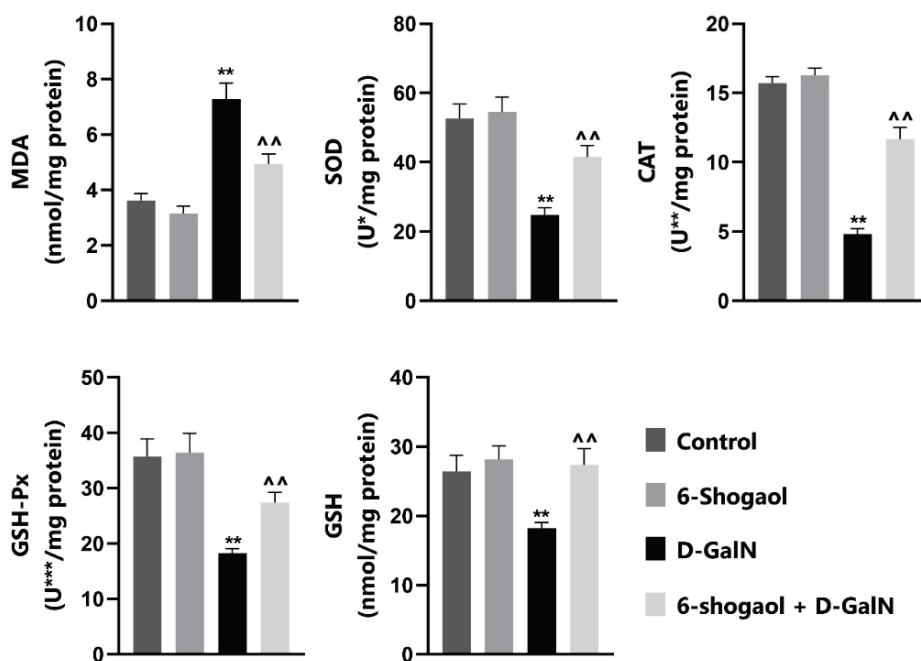


Fig. 3. Effects of 6-shogaol on hepatic MDA, SOD, CAT, GSH-Px and GSH levels in D-GalN-induced hepatotoxic and control rats. All data are presented as means \pm SEM (n = 6 in each group). **p<0.05 vs. control group; ^^p<0.05 vs. D-GalN group. U*-Enzyme concentration required for 50 % inhibition of nitroblue tetrazolium reduction in one minute. U**- μ mol of hydrogen peroxide consumed per minute. U***- μ g of glutathione consumed per minute.

Inflammatory cytokines in serum

The serum levels of the inflammatory cytokines TNF- α , IL-6, and IL-1 β were considerably elevated (P<0.05) in D-GalN-induced rats compared to control rats (Fig. 4.). Pretreatment with 6-shogaol dramatically reduced (P<0.05) inflammatory markers compared to D-GalN-induced animals.

Inflammatory markers expression by real-time PCR

As seen in Fig. 5. D-GalN-induced rats had significantly higher TNF- α , IL-6, NF- κ B and COX-2 expression levels than healthy control rats (P<0.05). Pretreatment with 6-shogaol resulted in noticeably decreased expression of TNF- α , IL-6, NF- κ B and COX-2 compared to D-GalN-induced animals.

p38, JNK and ERK expression by western blot analysis

Fig. 6. depicts a Western blot analysis of p38,

Lipid peroxidative markers and antioxidant status

The quantitative examination of MDA, SOD, CAT, GPx, and GSH (Fig. 3.) served as indicators for evaluating oxidant damages generated by D-GalN. D-GalN dramatically decreased SOD, CAT, GPx, and GSH activity/levels while increasing MDA levels. In comparison to the D-GalN group, 6-shogaol pretreatment successfully decreased MDA levels (P<0.05) and considerably enhanced the levels of liver SOD, CAT, GPx, and GSH (P<0.05).

JNK, and ERK expression in rats induced with D-GalN. The protein expression of phosphorylated p38, JNK, and ERK was considerably increased (P<0.05) in D-GalN-induced rats compared to normal control rats. Significantly decreased phosphorylated p38, JNK, and ERK levels were seen when 6-shogaol was administered. p38, p-JNK and p-ERK protein expressions was performed by densitometric analysis with normalized to β -actin normalized with beta-actin (6B, C and D).

Discussion

Oxidative stress and inflammation are thought to be closely linked biological events that play a role in the development of many diseases, such as liver toxicity [20]. Scientific evidence suggests that D-GalN causes liver damage through oxidative stress and inflammatory

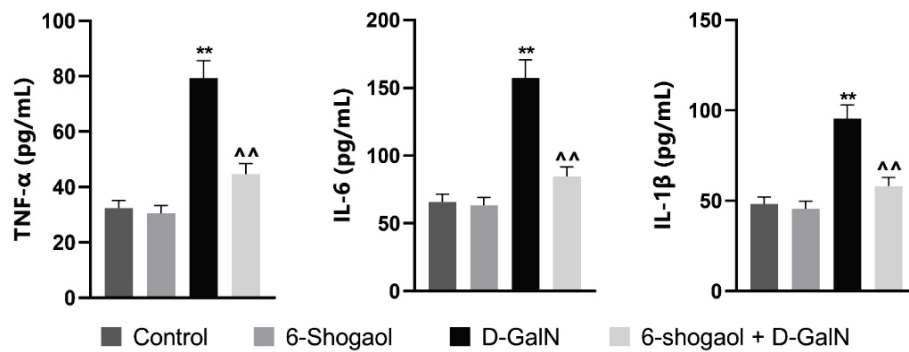


Fig. 4. Effect of 6-shogaol on inflammatory markers level in the serum of D-GalN-induced hepatotoxic and control rats. All data are presented as means \pm SEM (n = 6 in each group). **p<0.05 vs. control group; ^^p<0.05 vs. D-GalN group.

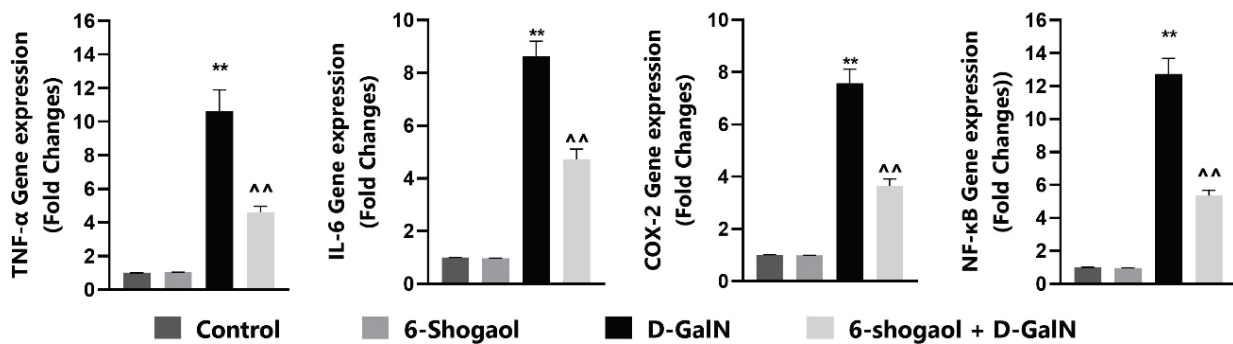


Fig. 5. Effect of 6-shogaol on inflammatory marker gene expression in the liver tissue of D-GalN-induced hepatotoxic and control rats. Effects of 6-shogaol on TNF- α , COX-2 and NF- κ B expression were measured by real time PCR. Relative expressions were performed with normalized to GAPDH. All data are presented as means \pm SEM (n = 3 in each group). **p<0.05 vs. control group; ^^p<0.05 D-GalN group.

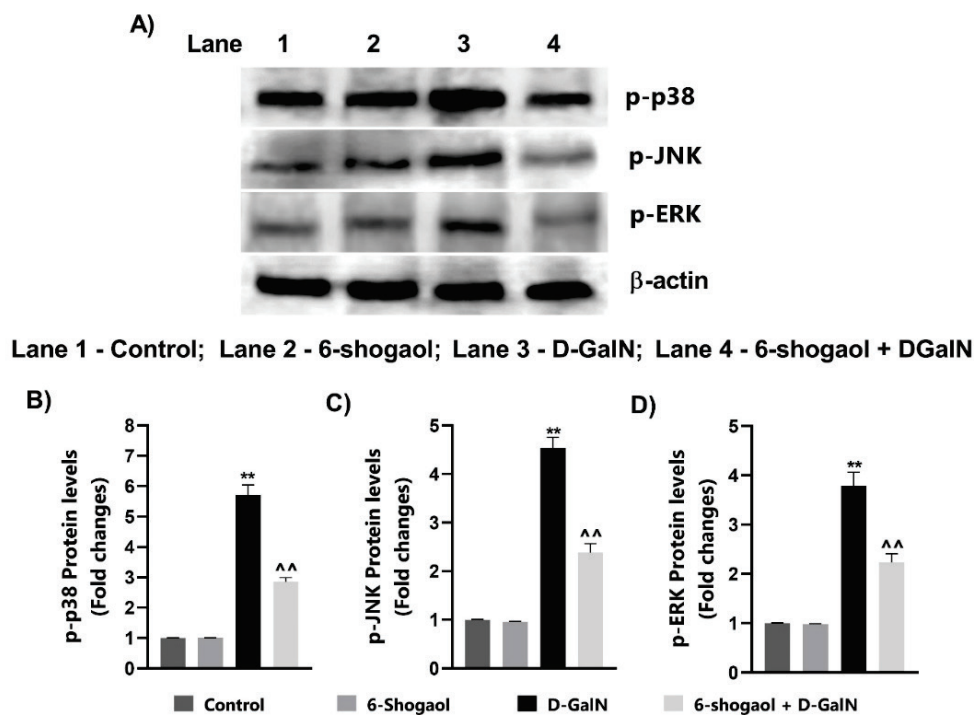


Fig. 6. Effect of 6-shogaol on MAPK signaling pathway in the liver tissue of D-GalN-induced hepatotoxic and control. A. Effects of 6-shogaol on p-P38, p-JNK, and p-ERK, protein expressions was measured by Western blotting. B, C, D. Protein expressions were performed by densitometric analysis normalized to β -actin. All data are presented as means \pm SEM (n = 3 in each group). **p<0.05 vs. control group; ^^p<0.05 D-GalN group.

responses similar to those caused by viral hepatitis [21]. Researchers have found that 6-shogaol has several biological effects, such as antioxidant, anti-inflammatory, and antiapoptotic properties [11,12]. So, this study aimed to determine if 6-shogaol had antioxidant, anti-inflammatory, and antiapoptotic effects in rats with liver damage caused by D-GalN.

D-GalN-induced rats, the plasma membrane was damaged, resulting in enzyme leakage from the cell and increased serum enzyme levels. Elevated serum enzyme levels indicate liver cell membrane leakage and a loss of functional integrity. Therefore, a significant increase in transaminases could be interpreted as liver damage. Although the serum marker enzymes (AST, ALT) usually are cytoplasmic, liver damage causes them to leak into the bloodstream due to altered membrane permeability [22]. Oral administration of 6-shogaol to prevent cellular leakage and the loss of the functional integrity of the cell membrane in hepatocytes may have hepatoprotective effects. In addition, our results were validated by an H&E study that revealed pathological alterations, including cellular necrosis and infiltration of inflammatory cells. The preceding results suggested the presence of liver damage. In contrast, Pretreatment with 6-shogaol restored hepatic function, as evidenced by reduced pathological conditions and transaminase activity.

In the event of liver injury, an imbalance between the production of free radicals and the action of antioxidants would likely contribute to oxidative stress and lipid peroxidation [20]. D-GalN exposure modifies the antioxidant system of the liver and leads to biological lipid peroxidation. The activity of antioxidant enzymes, including SOD, CAT, GSH, and GSH-Px, are reported to decline in response to D-GalN stimulation [23]. In addition, MDA, the final product of lipid breakdown and a dependable measure of oxidative stress, is elevated in rats triggered by D-GalN [2]. Our present research shows that 6-shogaol administration dramatically decreased MDA levels and restored the activities of SOD, CAT, GSH, and GSH-Px. These analytical findings indicated that the protection of 6-shogaol impact might be attributable to its antioxidative properties. This result was supported by previous research that stated that 6-shogaol has potent antioxidant activity reducing ROS-induced lipid peroxidation [11,12]. Suresh *et al.* [24] reported that ginger bioactive compound (6)-paradol significantly decreased the TBARS levels in experimental animals, which suggests that (6)-paradol has anti-lipid peroxidative effect in oral carcinogenesis.

Inflammation is one of the most prevalent causes of many clinical disorders related to oxidative stress [25]. TNF- α , IL-6 and IL-1 β are inflammatory cytokines that play a significant role in liver injury and can cause hepatocyte apoptosis and necrosis [26]. When D-GalN stimulates liver macrophages and Kupffer cells, inflammation is ultimately driven by the invasion of inflammatory cells and the excessive production of pro-inflammatory cytokines [27]. It has been noted that D-GalN-induced hepatotoxic rats have altered levels of pro-inflammatory cytokines like TNF- α , IL-6 and IL-1 β [28]. This investigation discovered that 6-shogaol dramatically lowered TNF- α , IL-6 and IL-1 β in rats with LPS/D-GalN administration. According to the findings, 6-shogaol might shield mice from 6-shogaol generated by LPS/DGalN via regulating inflammatory and oxidative responses.

p38 MAP kinase (MAPK)-mediated signaling is closely connected signal cascades governing cytokine synthesis and stress response. It has been confirmed that MAPK signaling pathways are essential in controlling inflammatory mediators [29]. Hyperphosphorylation of the p38 MAPK pathway activates NF- κ B and results in the production of inflammatory proteins, which ultimately cause inflammation of the liver [30]. Most researchers have examined three parallel subfamilies of ERK, p38, and JNK about inflammation-related disorders. Activation of p38 is often required for the production of several inflammatory molecules. The ERK pathway is also essential for regulating NO and various cytokines (including TNF- α , IL-1 β and IL-6). Continuous DGalN stimulation will trigger JNK activation and translocation to mitochondria, resulting in enhanced mitochondrial permeability conversion and liver cell death [31]. D-GalN injection enhanced the activation of ERK, JNK, and p38 MAPK in the present investigation. In contrast, phosphorylation of ERK, JNK, and p38 MAPK was reduced by 6-shogaol Pretreatment. Thus, 6-shogaol's anti-inflammatory of 6-shogaol action is tied to the MAPK signaling pathway.

Apoptosis is regarded as one of the principal causes of cell death in liver damage illnesses [32]. Oxidative stress stimulates numerous biological processes, such as proliferation and apoptosis. Bax and Bcl-2 are two essential representatives of the pro- and antiapoptotic protein families, respectively. The purpose of Bcl-2 is to prevent cell death, whereas Bax tends to hasten cell death. Casp 9 should be activated by the release of cytochrome C, controlled by Bcl-2 and

Bax [33]. In the present investigation, we found that 6-shogaol had hepatoprotective effects against D-GalN-induced hepatotoxicity by increasing the level of Bcl-2 protein and decreasing the amounts of Bax, Cyto-C, and Caspase 9 proteins. As demonstrated by the findings, the apoptotic signaling system may play a role in the hepatoprotective activity of 6-shogaol against hepatotoxicity.

Conclusion

The findings showed that 6-shogaol has

antioxidant, anti-inflammatory, and antiapoptotic properties against D-GalN-induced Hepatotoxicity. The possible mechanism focused primarily on antioxidant capacity, liver apoptosis inhibition, and regulation of inflammatory cytokines via MAPK signaling pathways. As a result, our findings imply that 6-shogaol protects against hepatotoxicity caused by D-GalN in rats.

Conflict of Interest

There is no conflict of interest.

References

1. Koblíhová E, Mrázová I, Vaňourková Z, Maxová H, Kikerlová S, Husková Z, Ryska M, Froněk J, Vernerová Z. 2020. Pharmacological stimulation of Wnt/ β -catenin signaling pathway attenuates the course of thioacetamide-induced acute liver failure. *Physiol Res* 2023;69:113. <https://doi.org/10.33549/physiolres.934071>
2. Ansari MA, Ahmad SF, Khan MR, Bakheet SA, Raish M, Bin Jordan YA, Shahid M, Haq N, Ahmad A. Sinapic acid ameliorates D-galactosamine/lipopolysaccharide-induced fulminant hepatitis in rats: Role of nuclear factor erythroid-related factor 2/heme oxygenase-1 pathways. *World J Gastroenterol* 2021;27:592-608. <https://doi.org/10.3748/wjg.v27.i7.592>
3. Mao J, Yi M, Wang R, Huang Y, Chen M. Protective effects of costunolide against D-galactosamine and lipopolysaccharide-induced acute liver injury in mice. *Front Pharmacol* 2018;9:1469. <https://doi.org/10.3389/fphar.2018.01469>
4. Nair RR, Suja SR, Aneeshkumar AL, Bhaskar S, Vilash V, Rajasekharan S. Ameliorative effect of ethanolic extract of roots of *Tetracera akara* (Burm. f.) Merr. on D-galactosamine induced hepatotoxicity in Wistar rats by downregulation of inflammatory mediators like TNF α , COX-2 and iNOS. *Indian J Exp Biol* 2020;58:161-171. <https://doi.org/10.56042/ijeb.v58i03.65448>
5. Yu Z, Ding Y, Zeng T, Zhao X, Zhang C. Hepatoprotective effect of diallyl trisulfide against lipopolysaccharide and D-galactosamine induced acute liver failure in mice via suppressing inflammation and apoptosis. *Toxicol Res (Camb)*. 2022;11(2):263-271. <https://doi.org/10.1093/toxres/tfac005>
6. Yue J, López JM. Understanding MAPK Signaling Pathways in Apoptosis. *Int J Mol Sci* 2020; 21:2346. <https://doi.org/10.3390/ijms21072346>
7. Aamani N, Bagheri A, Qajari NM, Shafaroudi MM, Khonakdar-Tarsi A. JNK and p38 gene and protein expression during liver ischemiareperfusion in a rat model treated with silibinin. *Iran J Basic Med Sci* 2022;25:1373-13818. <https://doi.org/10.22038/IJBMS.2022.60550.13422>
8. Islam MS, Yu H, Miao L, Liu Z, He Y, Sun H. Hepatoprotective effect of the ethanol extract of *Illicium henryi* against acute liver injury in mice induced by lipopolysaccharide. *Antioxidants* 2019;8: 446. <https://doi.org/10.3390/antiox8100446>
9. Kou X, Wang X, Ji R, Liu L, Qiao Y, Lou Z, Ma C, Li S, Wang H, Ho CT. Occurrence, biological activity and metabolism of 6-shogaol. *Food Funct* 2018;9:1310-1327. <https://doi.org/10.1039/C7FO01354J>
10. Han HS, Kim KB, Jung JH, An IS, Kim YJ, An S. Anti-apoptotic, antioxidant and anti-aging effects of 6-shogaol on human dermal fibroblasts. *Biomed Dermatol* 2018;27:2. <https://doi.org/10.1186/s41702-018-0037-4>
11. Kode J, Maharana J, Dar AA, Mukherjee S, Gadewal N, Sigalapalli DK, Kumar S, Panda D, Ghosh S, Keshry SS, Mamidi P. 6-Shogaol Exhibits Anti-viral and Anti-inflammatory Activity in COVID-19-Associated Inflammation by Regulating NLRP3 Inflammasomes. *ACS Omega* 2023;8:2618-2628. <https://doi.org/10.1021/acsomega.2c07138>

12. Annamalai G, Suresh K. [6]-Shogaol attenuates inflammation, cell proliferation via modulate NF- κ B and AP-1 oncogenic signaling in 7,12-dimethylbenz[a]anthracene induced oral carcinogenesis. *Biomed Pharmacother* 2018;98:484-490. <https://doi.org/10.1016/j.biopha.2017.12.009>
13. Sapkota A, Park SJ, Choi JW. Neuroprotective Effects of 6-Shogaol and Its Metabolite, 6-Paradol, in a Mouse Model of Multiple Sclerosis. *Biomol Ther (Seoul)* 2019;27:152-159. <https://doi.org/10.4062/biomolther.2018.089>
14. Bischoff-Kont I, Primke T, Niebergall LS, Zech T, Fürst R. Ginger Constituent 6-Shogaol Inhibits Inflammation- and Angiogenesis-Related Cell Functions in Primary Human Endothelial Cells. *Front Pharmacol* 2022;13:844767. <https://doi.org/10.3389/fphar.2022.844767>
15. Hsu CM, Su HC, Yang MY, Tsai YT, Tsai MS, Yang YH, Wu CY, Chang SF. 6-shogaol is a potential treatment for Head and Neck Squamous Cell Carcinoma. *Int J Med Sci* 2023;20:238-246. <https://doi.org/10.7150/ijms.80542>
16. Gratal P, Mediero A, Lamuedra A, Matamoros-Recio A, Herencia C, Herrero-Beaumont G, Martín-Santamaría S, Largo R. 6-Shogaol (enexasogol) treatment improves experimental knee osteoarthritis exerting a pleiotropic effect over immune innate signaling responses in chondrocytes. *Br J Pharmacol* 2022;179:5089-5108. <https://doi.org/10.1111/bph.15908>
17. Najmi AK, Pillai KK, Pal SN, Aqil M. Free radical scavenging and hepatoprotective activity of jigrine against galactosamine induced hepatopathy in rats. *J Ethnopharmacol* 2005;97:521-525. <https://doi.org/10.1016/j.jep.2004.12.016>
18. Radhiga T, Sundaresan A, Viswanathan P, Pugalendi KV. Effect of protocatechuic acid on lipid profile and DNA damage in D-galactosamine-induced hepatotoxic rats. *J Basic Clin Physiol Pharmacol*. 2016;27:505-514. <https://doi.org/10.1515/jbcpp-2015-0135>
19. Thangaiyan R, Arjunan S, Govindasamy K, Khan HA, Alhomida AS, Prasad NR. Galangin attenuates isoproterenol-induced inflammation and fibrosis in the cardiac tissue of albino wistar rats. *Front Pharmacol* 2020;11:585163. <https://doi.org/10.3389/fphar.2020.585163>
20. Conde de la Rosa L, Goicoechea L, Torres S, Garcia-Ruiz C, Fernandez-Checa JC. Role of Oxidative Stress in Liver Disorders. *Livers* 2022;2:283-314. <https://doi.org/10.3390/livers2040023>
21. Wang L, Wang X, Kong L, Wang S, Huang K, Wu J, Wang C, Sun H, Liu K, Meng Q. Isoliquiritigenin alleviates LPS/D-GalN-induced acute liver failure by activating the PGC-1 α /Nrf2 pathway to reduce oxidative stress and inflammatory response. *Int Immuno pharmacol* 2021;100:108159. <https://doi.org/10.1016/j.intimp.2021.108159>
22. Huang S, Mo C, Zeng T, Lai Y, Zhou C, Xie S, Chen L, Wang Y, Chen Y, Huang S, Gao L, Lv Z. Lupeol ameliorates LPS/D-GalN induced acute hepatic damage by suppressing inflammation and oxidative stress through TGF β 1-Nrf2 signal pathway. *Aging (Albany NY)* 2021;13:6592-6605. <https://doi.org/10.18632/aging.202409>
23. Villanueva-Paz M, Morán L, López-Alcántara N, Freixo C, Andrade RJ, Lucena MI, Cubero FJ. Oxidative stress in drug-induced liver injury (DILI): From mechanisms to biomarkers for use in clinical practice. *Antioxidants* 2021;10:390. <https://doi.org/10.3390/antiox10030390>
24. Suresh K, Manoharan S, Vijayaanand MA, Sugunadevi G. Chemopreventive and antioxidant efficacy of (6)-paradol in 7, 12-dimethylbenz (a) anthracene induced hamster buccal pouch carcinogenesis. *Pharmacol Rep* 2010;62:1178-85. [https://doi.org/10.1016/S1734-1140\(10\)70380-7](https://doi.org/10.1016/S1734-1140(10)70380-7)
25. Dong W, Song E, Song Y. Co-administration of lipopolysaccharide and D-galactosamine induces genotoxicity in mouse liver. *Sci Rep* 2021;11:1733. <https://doi.org/10.1038/s41598-021-81383-5>
26. Gong J, Tu W, Liu J, Tian D. Hepatocytes: A key role in liver inflammation. *Front Immunol* 2023;13:1083780. <https://doi.org/10.3389/fimmu.2022.1083780>
27. Wen Y, Lambrecht J, Ju C, Tacke F. Hepatic macrophages in liver homeostasis and diseases-diversity, plasticity and therapeutic opportunities. *Cell Mol Immunol* 2021;18:45-56. <https://doi.org/10.1038/s41423-020-00558-8>
28. Kemelo MK, Canová NK, Horinek A, Farghali H. Sirtuin-activating compounds (STACs) alleviate D-galactosamine/lipopolysaccharide-induced hepatotoxicity in rats: involvement of sirtuin 1 and heme oxygenase 1. *Physiol Res* 2017;66:497-505. <https://doi.org/10.33549/physiolres.933488>
29. Ren Y, Wang LH, Deng FS, Li JS, Jiang L. Protective effect and mechanism of alpha-lipoic acid on partial hepatic ischemia-reperfusion injury in adult male rats. *Physiol Res* 2019;68:739-745. <https://doi.org/10.33549/physiolres.934095>

-
30. Westenberger G, Sellers J, Fernando S, Junkins S, Han SM, Min K, Lawan A. Function of Mitogen-Activated Protein Kinases in Hepatic Inflammation. *J Cell Signal* 2021;2:172-180.
 31. Heslop KA, Rovini A, Hunt EG, Fang D, Morris ME, Christie CF, Gooz MB, DeHart DN, Dang Y, Lemasters JJ, Maldonado EN. JNK activation and translocation to mitochondria mediates mitochondrial dysfunction and cell death induced by VDAC opening and sorafenib in hepatocarcinoma cells. *Biochem Pharmacol* 2020;171:113728. <https://doi.org/10.1016/j.bcp.2019.113728>
 32. Shojaie L, Iorga A, Dara L. Cell death in liver diseases: a review. *Int J Mol Sci* 2020;21:9682. <https://doi.org/10.3390/ijms21249682>
 33. Ghorbanpour A, Salari S, Baluchnejadmojarad T, Roghani M. Capsaicin protects against septic acute liver injury by attenuation of apoptosis and mitochondrial dysfunction. *Heliyon* 2023;9:e14205. <https://doi.org/10.1016/j.heliyon.2023.e14205>
-